

Periacetabular Osteotomy

Preoperative Radiographic Predictors of Outcome

Stephen Murphy, MD^{,**,*†}; and Rahul Deshmukh, MD[†]*

Periacetabular osteotomy is an extremely effective treatment for the spherical dysplastic hip without significant secondary osteoarthritis. Yet, the reliability of the procedure in patients with some degree of secondary osteoarthritis, asphericity, or associated deformities remains undefined. The purpose of the current study was to analyze a group of patients treated by periacetabular osteotomy for dysplasia to identify preoperative factors that predict outcome. Ninety-five consecutive hips in 87 patients treated by periacetabular osteotomy were studied prospectively. Of this group, 52 hips in 49 patients were studied for a minimum of 2 years after surgery. Forty-six of the 52 procedures resulted in hips with stable or improved cartilage space intervals. By Tonnis category, there were 0 of 21 failures in Grade 1, four of 22 failures in Grade 2 (18%), one of eight failures in Grade 3 (12.5%), and one of one failure in Grade 4 hips. Five of the six failures had factors identifiable on preoperative radiographs that separated these hips from the successful reconstructions. This study shows that periacetabular osteotomy can reliably produce a stable hip, even in the presence

of Grade 3 arthrosis, provided that the joint shows an improved cartilage space interval on the preoperative functional radiographs.

Uncorrected hip dysplasia leads to secondary osteoarthritis²⁰ and is the most common etiology hip osteoarthritis treated by total hip arthroplasty in young patients.^{1,19} Periacetabular osteotomy now is established as an extremely effective treatment to delay and possibly prevent osteoarthritis of the dysplastic hip.^{5,16,17,18,22,23,25,26,29,30,31,33,34} The ideal candidate for this surgery is the patient with concentric motion, spherical joint surfaces, and no secondary arthritis or femoral deformity. Unfortunately, most patients who present with symptomatic hip dysplasia have hips that are not ideal. Patients would be served better if the surgeon were able to clearly predict, simply based on preoperative examination and radiographs, which hips would do well after joint-preserving surgery and which hips would not do well. Unfortunately, there are currently no studies that specify how to clearly separate these two groups.^{25,29,33} Many factors can be identified preoperatively that may affect outcome. Measurable factors include the degree of secondary osteoarthritis, sphericity of the joint surfaces, severity of the acetabular dysplasia, and severity of any associated femoral deformities. The current authors prospectively analyze these preoperative variables in a consecutive group of patients treated by periacetabular

From the *Beth Israel-Deaconess Medical Center, Boston, MA; the **New England Baptist Bone and Joint Institute, Boston, MA; and †Harvard Medical School, Boston, MA.

The study was funded in part by the AO/ASIF Foundation. Neither of the authors have any financial interest regarding the topic of this manuscript.

Reprint requests to Stephen B. Murphy, MD, Boston Orthopedic Group, 1269 Beacon Street, Brookline, MA 01446. Phone: 617-739-2525; Fax: 617-731-9212.

DOI: 10.1097/01.blo.0000038466.05771.d9

osteotomy to identify preoperative factors that may predict outcome.

METHODS AND METHODS

Ninety-five consecutive hips in 87 patients treated by periacetabular osteotomy for symptomatic hip dysplasia were studied prospectively. Patients were evaluated clinically and radiographically with an anteroposterior (AP) radiograph of the pelvis and a false profile view of the affected hip (Fig 1A). Patients with limited motion, subluxation, secondary osteoarthritis, or joint surfaces that appeared aspherical also had functional radiographic evaluation. Functional radiographs include an AP radiograph of the pelvis with the hip in maximum abduction and a false profile view with the hip flexed (Fig 1B). These views can be taken as plain radiographs or as part of

a fluoroscopic examination of the hip done by the surgeon. These radiographs were taken to simulate the appearance of the hip after periacetabular osteotomy. The abduction view is intended to simulate the appearance of the hip with improved lateral coverage. The false-profile view with the hip in flexion is intended to simulate the appearance of the hip with improved anterior coverage (Fig 1C).

The periacetabular osteotomy was done by making an incision over the anterior aspect of the hip and first doing a partial osteotomy of the ischium deep to the psoas tendon and obturator externus muscle. The hip was evaluated by arthrotomy for treatment of intraarticular disorders. Unstable labral tissue and intraarticular ganglia were excised. Areas of exposed bone were drilled or picked. Impingement was relieved by femoral head or neck debridement.^{24,28} An osteotomy of the superior pubic ramus was done followed by an incomplete, transverse osteotomy of the

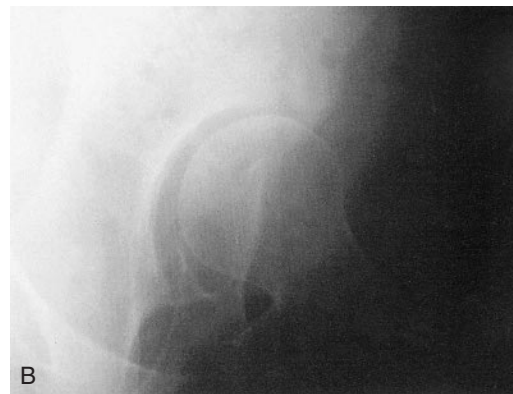
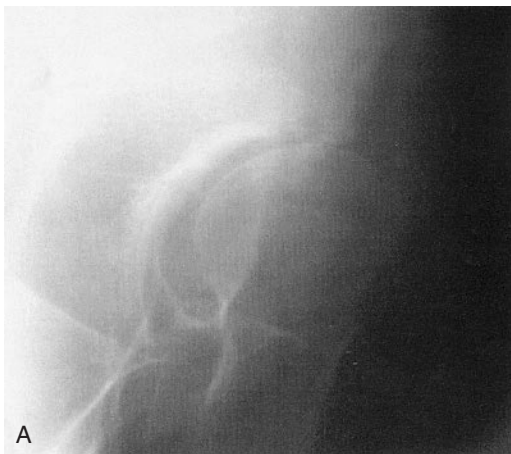
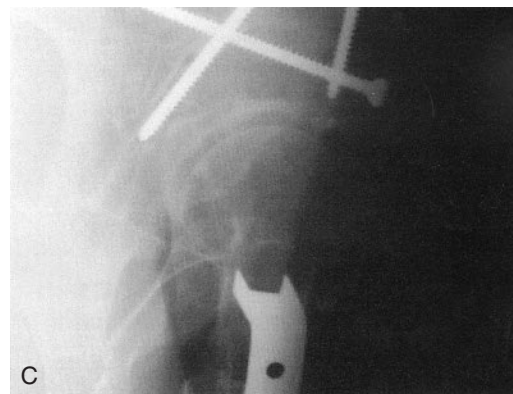
Fig 1A–C. (A) A false profile view of the hip of a 35-year-old woman shows subluxation anteriorly, laterally, and superiorly. The false profile view was taken with the patient standing with the affected hip closest to the radiographic plate and pelvis rotated 25° from straight lateral. (B) A false profile view with the hip in flexion shows an improved appearance of the joint. This is a functional radiograph taken to simulate the appearance of the hip with improved anterior coverage. The technique is the same as the false profile view with the exception that the hip is flexed with the foot on a footstool. (C) A false profile view of the same hip taken after periacetabular and femoral osteotomy shows a stable, reduced hip.



ilium from just below the anterosuperior iliac spine to the region of the pelvic brim. A retroacetabular osteotomy then was done from the pelvic brim along the inside of the pelvis behind the acetabulum and parallel to the posterior column. The final osteotomy was done across the anterior portion of the ischium underneath the acetabulum to complete the separation of the acetabulum from the remaining pelvis. The acetabulum was positioned to correct the deformity, aiming to place the weightbearing surface horizontal on the AP view (irrespective of the lateral center edge angle) and to achieve an anterior center edge angle of more than 20°. The procedure was done in a manner identical to the original Bernese periacetabular osteotomy⁵ with two exceptions. All of the procedures were done with preservation of the abductors and the posterior column was left fully intact.²² Of the 95 hips, 52 hips in 49 patients were studied for a minimum of 2 years after surgery. Thirty-six hips (69%) were in females and 16 hips (31%) were in males. Patients had a mean age of 35.1 ± 8.1 years (range, 15.8–55.1 years). The mean followup was 5.4 ± 2.6 years (range, 2.1–9.6 years). Variables measured included lateral center edge angle, anterior center edge angle,¹⁰ femoral neck-shaft angle, femoral head articular angle, degree of secondary osteoarthritis (Tonnis classification³²), and sphericity of the joint. Hips with subchondral sclerosis were classified as Grade 1. Hips with subchondral cyst formation and partial cartilage interval narrowing were classified as Grade 2. Hips with severe or complete but localized cartilage interval narrowing were classified as Grade 3. Grade 4 hips had extensive and severe or complete cartilage interval loss. Spherical joints were defined as those that either had matching, spherical joint surfaces on the AP radiograph of the pelvis and false profile views of the affected hip, or had concentric motion on preoperative functional radiographic evaluation, even if the joint surfaces were not perfectly spherical. Aspherical joints were defined as those that did not have concentric motion on preoperative functional radiographic evaluation. Data from the group of patients with stable reconstructions were compared with data from the group of patients who had failed results. Failure was defined by either conversion to total hip arthroplasty or Grade 4 osteoarthritis.

RESULTS

All osteotomies healed with the exception of two superior pubic rami, one of which was bone

grafted. Two osteotomies were slow to heal but healed within 1 year without bone grafting or additional surgery. There were no infections and one partial peroneal palsy. The lateral femoral cutaneous nerve was affected in the majority of patients although the nerve's long-term function was not quantified. There were no other neurologic or vascular complications. Two patients had pelvic hardware removal. One patient had arthroscopy 6 years postoperatively for a torn acetabular labrum.

Preoperatively, none of the hips were Tonnis Grade 0, 21 hips were Grade 1, 22 hips were Grade 2, eight hips were Grade 3, and one hip was Grade 4. The lateral center edge angle averaged $4.2^\circ \pm 9.5^\circ$ (range, -21° – 24°) and the anterior center edge angle averaged $5.6^\circ \pm 12.4^\circ$ (range, -40° – 23°). Postoperatively, the lateral center edge angle averaged $31^\circ \pm 10.7^\circ$ (range, 5° – 54°) and the anterior center edge angle averaged $33.8^\circ \pm 11.3^\circ$ (range, 10° – 56°).

Six of the 52 hips failed. None was Grade 0 or 1, four were Grade 2, one was Grade 3, and one was Grade 4 preoperatively.

Looking specifically at the hips with Grades 1 and 2 osteoarthritis preoperatively, there was one of 40 failures in hips with spherical motion. That one failure was attributable to loss of appropriate correction in the early postoperative period and a femoral deformity that was not corrected surgically. This hip had a lateral center edge angle of 8° postoperatively and a femoral articular surface that was tilted laterally 30° . Based on these measurements, this hip had the most severe postoperative dysplasia of the 52 hips. Two of the four Grade 2 hips that failed had aspherical motion that could not be improved surgically. The remaining Grade 2 hip that failed had a false acetabulum.

Only one of the eight Grade 3 hips failed and could be distinguished from the other Grade 3 hips in that the superolateral cartilage interval narrowing did not improve on the preoperative abduction view (Fig 2). The seven other Grade 3 hips all showed the absence of localized narrowing on functional radiographs (Fig 3). These seven of the eight hips with Grade 3 osteoarthritis had stable cartilage space

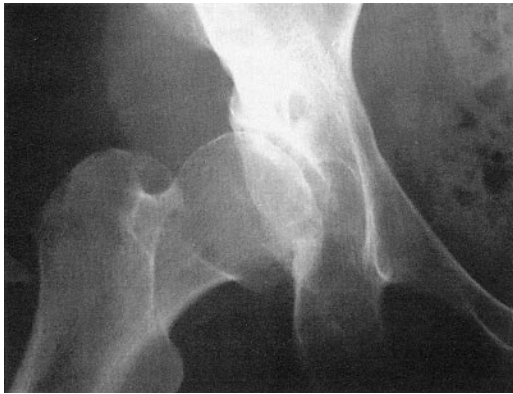


Fig 2. The anteroposterior radiograph of a 42-year-old woman shows the hip in abduction. The cartilage interval is narrowed at the lateral aspect of the joint. Acetabular redirection failed within 2 years.

intervals develop despite very severe localized cartilage interval narrowing visible on the presenting AP or false profile radiographs of the hip in a neutral position.

The only Grade 4 hip failed. This hip was concentric but obviously failed simply because the joint was worn out extensively at the time of surgery. Time to failure in all hips that failed was within 2 years. Radiographic findings clearly predictive of impending failure were visible well within a year of surgery in all of these cases. There was no statistical significance between age, weight, severity of dysplasia, or degree of femoral deformity and outcome.

DISCUSSION

The current study shows that dysplastic hips with Grades 0 to 2 osteoarthritis and spherical motion had successful reconstructions during the period of followup provided that appropriate correction was achieved (39 of 40 hips).

The study also shows that even dysplastic hips with Grade 3 osteoarthritis can do very well clinically provided that preoperative functional radiographs show improvement in the appearance of the joint, with disappearance of severe, localized cartilage interval narrowing. Also, the study confirms previous findings²⁹

that hips with asphericity that cannot be corrected surgically are at the highest risk of failure, irrespective of the degree of osteoarthritis.

The study results suggest that all hips with Grade 3 osteoarthritis or aspherical joint surfaces should be evaluated with functional radiographs. The two critical views are the AP radiograph of the pelvis with the hips in abduction and the false-profile view of the affected hip in flexion. The AP radiograph of the pelvis in abduction simulates the appearance of the joint with proper lateral coverage and the false-profile view in flexion simulates the appearance of the joint with proper anterior coverage. These views often show proper reduction of the subluxated joint and improvement in the cartilage space interval. The demonstration of these desired findings on functional radiographic assessment suggests that the hip will respond well to acetabular redirection. Conversely, the only Grade 3 hip that did not show improvement on functional radiographs failed.

If the patient's hip has greater passive than active abduction on examination for reasons such as pain or inflammation, the hip should be positioned passively for the functional radiographs. Especially complex hips may be evaluated by the surgeon under fluoroscopy to obtain the function radiographs and a better understanding of the joint kinematics.

Because approximately all of the severe femoral deformities were corrected at the time of periacetabular osteotomy, the results of this study cannot be used to develop criteria for femoral osteotomy indications. The one failure of a spherical hip with Grade 2 osteoarthritis clearly had inadequate correction of the acetabular deformity and no surgery to correct the severe femoral deformity. The primary limitation of the current study is the small number of hips studied (52) and the even smaller number of failures to analyze (six).

The current study did not focus on a correlation between preoperative magnetic resonance imaging (MRI) findings and outcome as most of the patients did not have MRI studies preoperatively and the quality and technique of

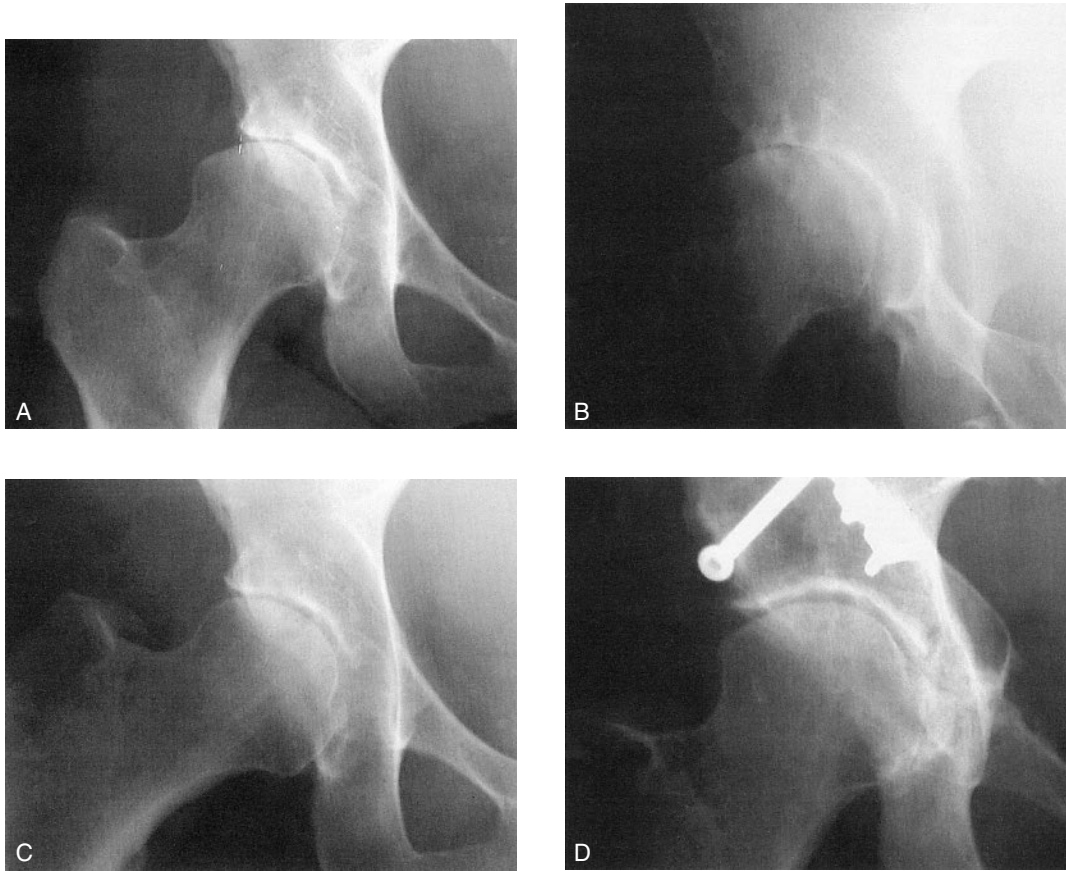


Fig 3A–D. Anteroposterior radiograph of a 47-year-old woman with hip dysplasia shows cartilage interval narrowing, subchondral sclerosis, and cyst formation. (B) False profile view of the same hip shows focal bone-on-bone findings in the anterosuperior portion of the joint. (C) Anteroposterior radiograph of the hip in abduction shows spherical motion and an even cartilage interval. (D) Anteroposterior radiograph shows a well-maintained cartilage interval 10 years after acetabular redirection. The patient has a Harris hip score of 100 points.

these studies varied widely.^{4,6,8,11,12,27} Because routine MRI evaluations currently do not allow for dynamic assessment of the hip during motion, the most critical information about the hip joint cannot be ascertained from preoperative MRI studies. In fact, MRI findings such as localized cartilage loss, labral avulsions, and cyst formation can be predicted based on preoperative radiographic findings.¹³ Of greater concern is that these severely abnormal findings on MRI studies may dissuade the surgeon from recommending joint-preserving surgery to patients who would benefit greatly by it.

Although MRI studies may have little, if any, role in determining the indications for surgery, they may be useful in alerting the surgeon to the location and nature of intraarticular disorders that could be addressed at the time of arthrotomy.

Similarly, preoperative mechanical analysis and simulation of acetabular redirection surgery^{2,7,9,14,15,21} probably has a role in refining the surgical plan, but currently does not have a role in determining indications and contraindications for surgery. Current mechanical predictions of hip contact pressures based on

CT studies assume that the hip is spherical and in full contact with the available acetabular surface. These mechanical analyses do not yet account for subluxation, asphericity, hip kinematics, or preexisting osteoarthritis which, based on the current study, are the most important factors predictive of outcome after periacetabular osteotomy. Computerized simulation would require incorporation of joint kinematics and assessment of joint congruity before it's current usefulness could be extended to the role of patient selection.

The one case of rotating a false acetabulum proved unsuccessful. This case alone cannot be used to determine outcome of periacetabular osteotomy for false acetabuli. However, the general experience with redirection of the false acetabulum has been poor (verbal communication, R Ganz, MD, 2002) and salvage augmentation procedures such as the shelf or Chiari osteotomy may have a role in treating these hips.^{3,35} Based on the current study, an excellent prognosis after periacetabular osteotomy can be anticipated for spherical hips with Grades 0 to 2 osteoarthritis and a good prognosis after periacetabular osteotomy can be anticipated for spherical hips with Grade 3 osteoarthritis provided that the appearance of the joint improves on functional radiographs. Aspherical hips represent special, high risk cases that need to be considered individually.

Acknowledgments

The authors thank Doctors Michael Millis, John Hall, and Robert Poss and Professors Reinhold Ganz, Heinz Wagner, Maurice Muller, and Renato Bombelli for teaching and guidance.

References

1. Aronson J: Osteoarthritis of the young adult: Etiology and treatment. *Instr Course Lect* 35:119-128, 1986.
2. Brand RA: Hip osteotomies: A biomechanical consideration. *J Am Acad Orthop Surg* 5:282-291, 1997.
3. Calvert PT, August AC, Albert JS, Kemp HB, Catterall A: The Chiari pelvic osteotomy. *J Bone Joint Surg* 69B:551-555, 1987.
4. Dorrell JH, Catterall A: The torn acetabular labrum. *J Bone Joint Surg* 68B:400-403, 1986.
5. Ganz R, Klaue K, Vinh TS, Mast JW: A new periacetabular osteotomy for the treatment of hip dysplasias: Technique and preliminary results. *Clin Orthop* 232:26-36, 1988.

6. Hasegawa Y, Fukatsu H, Matsuda T, Iwase T, Iwata H: Magnetic resonance imaging in osteoarthritis of the dysplastic hip. *Arch Orthop Trauma Surg* 115:243-248, 1996.
7. Hipp J, Sagano D, Millis MB, Murphy SB: Planning acetabular redirection osteotomies based on joint contact pressures. *Clin Orthop* 364:134-143, 1999.
8. Klaue K, Durnin CW, Ganz R: The acetabular rim syndrome: A clinical presentation of dysplasia of the hip. *J Bone Joint Surg* 73B:423-429, 1991.
9. Klaue K, Wallin A, Ganz R: CT evaluation of coverage and congruency of the hip prior to osteotomy. *Clin Orthop* 232:15-25, 1988.
10. Lequesne M, de Sèze S: Le faux profil du bassin: Nouvelle incidence radiographique pour l'étude de la hanche: Son utilité dans les dysplasies et les différentes coxopathies. *Rev Rhum* 28:643-652, 1961.
11. Leunig M, Werlen S, Ungersböck A, Ito K, Ganz R: Evaluation of the acetabular labrum by MR arthrography. *J Bone Joint Surg* 79B:230-234, 1997.
12. Mast JW, Mayo KA, Chosa E, Berlemann U, Ganz R: The acetabular rim fracture: A variant of the acetabular rim syndrome. *Semin Arthroplasty* 8:97-101, 1997.
13. McCarthy J, Lee J: Acetabular dysplasia: A paradigm of arthroscopic evaluation of chondral injuries. *Clin Orthop* 405:xxx-xxx, 2002.
14. Michaeli DA, Murphy SB, Hipp JA: Comparison of predicted and measured contact pressures in normal and dysplastic hips. *Med Eng Physics* 19:180-186, 1997.
15. Millis MB, Murphy SB: Use of CT reconstruction in planning osteotomy of the hip. *Clin Orthop* 274:154-159, 1992.
16. Millis MB, Murphy SB: The Boston concept: Periacetabular osteotomy with simultaneous arthrotomy via the direct anterior approach. *Orthopade* 27:751-758, 1998. In German.
17. Millis MB, Murphy SB, Poss R: Osteotomies about the hip for the prevention and treatment of osteoarthritis. *J Bone Joint Surg* 77A:626-647, 1995.
18. Murphy SB: Osteotomy of the pelvis. *Semin Arthroplasty* 8:88-96, 1997.
19. Murphy SB, Barsoum W: Ceramic-ceramic bearings in total hip arthroplasty: Preliminary clinical results. *J Orthop Harvard Med School* 3:92-94, 2001.
20. Murphy SB, Ganz R, Müller ME: The prognosis of untreated hip dysplasia: Factors predicting outcome. *J Bone Joint Surg* 77A:985-989, 1995.
21. Murphy SB, Kijewski PK, Millis MB, Harless A: Acetabular dysplasia in the adolescent and young adult. *Clin Orthop* 261:214-223, 1991.
22. Murphy SB, Millis MB: Peri-acetabular osteotomy without abductor dissection using the direct anterior exposure. *Clin Orthop* 364:92-98, 1999.
23. Murphy SB, Millis MB, Hall JE: Surgical correction of acetabular dysplasia in the adult: A Boston experience. *Clin Orthop* 363:38-44, 1999.
24. Myers SR, Eijer H, Ganz R: Anterior femoroacetabular impingement after periacetabular osteotomy. *Clin Orthop* 363:93-99, 1999.
25. Nakamura S, Ninomiya S, Takatori Y, Morimoto S, Umeyama T: Long-term outcome of rotational acetabular osteotomy: 145 hips followed for 10-23 years. *Acta Orthop Scand* 69:259-265, 1998.

26. Ninomiya S: Rotational acetabular osteotomy for the severely dysplastic hip in the adolescent and adult. *Clin Orthop* 247:127–137, 1989.
27. Pitto RP, Klaue K, Ganz R: Labrum lesions and acetabular dysplasia in adults. *Z Orthop Ihre Grenzgeb* 134:452–456, 1996. In German.
28. Reynolds D, Lucas J, Klaue K: Retroversion of the acetabulum: A cause of hip pain. *J Bone Joint Surg* 81B:281–288, 1999.
29. Schramm M, Pitto RP, Bär K, Meyer M, Rohm E, Hohmann D: Prophylaxis of secondary osteoarthritis with spherical osteotomy in residual acetabular dysplasia: Analysis of predictive factors of success. *Arch Orthop Trauma Surg* 119:418–422, 1999.
30. Siebenrock KA, Leunig M, Ganz R: Periacetabular osteotomy: The Bernese experience. *Instr Course Lect* 50:239–245, 2001.
31. Siebenrock KA, Scholl E, Lottenbach M, Ganz R: Bernese periacetabular osteotomy. *Clin Orthop* 363:9–20, 1999.
32. Tönnis D: *Congenital Dysplasia and Dislocation of the Hip in Children and Adults*. New York, Springer 1987.
33. Trousdale RT, Ekkernkamp A, Ganz R, Wallrichs SL: Periacetabular and intertrochanteric osteotomy for the treatment of osteoarthritis in dysplastic hips. *J Bone Joint Surg* 77A:73–85, 1995.
34. Wagner H: Osteotomies for Congenital Hip Dislocation. In Weil U (ed). *The Hip. Proceedings of the Fourth Open Scientific Meeting of the Hip Society*. St Louis, CV Mosby 45–65, 1976.
35. Windhager R, Pongracz N, Schönecker W, Kotz R: Chiari osteotomy for congenital dislocation and subluxation of the hip: Results after 20 to 34 years follow-up. *J Bone Joint Surg* 73B:890–895, 1991.