

# MINIMALLY INVASIVE, COMPUTER-ASSISTED VS CONVENTIONAL TOTAL HIP ARTHROPLASTY: A PROSPECTIVE ASSESSMENT OF SAFETY AND RECOVERY

Stephen B. Murphy MD

*Center for Computer Assisted and Reconstructive Surgery  
New England Baptist Bone and Joint Institute  
New England Baptist Hospital and Harvard Medical School*

## INTRODUCTION:

Computer-assisted, minimally invasive THA has the potential to speed recovery while simultaneously improving component position. Yet, some minimally invasive techniques have recently been reported to increase perioperative complication rates, including a high incidence of intraoperative femur fracture, cup malposition, and abductor injury. The current study prospectively measures recovery and complication rates following conventional THA and a new technique of minimally invasive THA using computer-assisted navigation and a superior capsulotomy.

## MATERIALS and METHODS:

123 ceramic-ceramic THA using conventional open surgery were compared to 89 ceramic-ceramic THA using a minimally-invasive, computer assisted technique. The conventional procedures were all performed using a modified direct lateral exposure. Conventional procedures that could not have been performed using the minimally invasive technique (eg extensive preexisting hardware, false acetabulum) were excluded to minimize selection bias. The minimally invasive, computer-assisted hips were all performed through a superior capsulotomy, anterior to the piriformis, posterior to the gluteus medius and minimus (figures 1 to 7). All of these procedures were performed using CT-based navigation (BrainLAB). Length of stay, use of walking aids at 1st followup and surgical complications were assessed.

## RESULTS:

Conventional THR patients averaged age 49, with an average length of stay of 4.3 days, and an average score of 1.9 points (out of 11) on the use of external support as defined by Harris Hip Score at 1st follow-up (6 weeks).

M-I/C-A patients averaged age 56 with an average length of stay of 3.8 days and a score of 6.2 for external support. The conventional group required three reoperations, one for a displaced greater trochanteric fracture and two for failure of abductor healing. There was also one intra-op greater trochanteric fracture repaired at surgery. The M-I/C-A group had one reoperation for displacement of the acetabular component repaired on post op day 3. This group had one intra-op greater trochanteric fracture identified and repaired at surgery. Neither group had hip dislocations. Cup position in the M-I/C-A group averaged 42.5 degrees of abduction (SD 2.9).

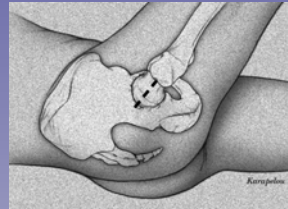

Figure 1. Left. Skin incision

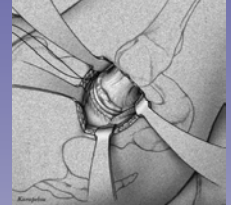

Figure 2. Right. Superior capsulotomy between piriformis (posterior) and minimus and medius (anterior)

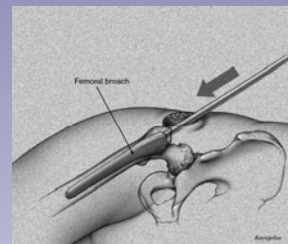


Figure 3. Left. Femoral preparation prior to femoral head excision

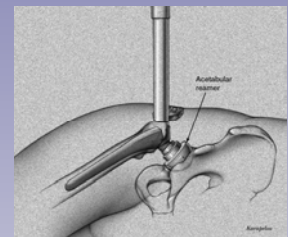


Figure 4. Right. Acetabular Preparation

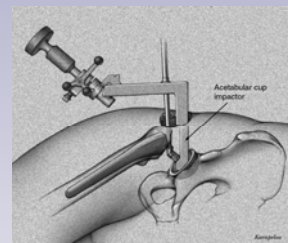


Figure 5. Left. Cup insertion

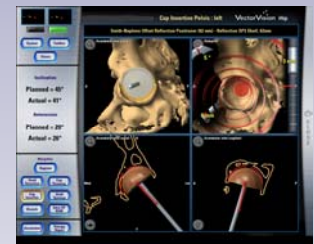

Figure 6. Right. Navigation of cup Insertion

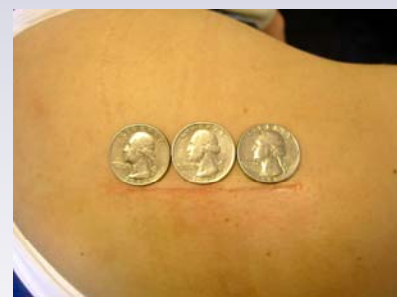

Figure 7. Left. Skin incision after Computer-assisted THR using a superior capsulotomy

## CONCLUSION:

Minimally invasive, computer-assisted THA using a superior capsulotomy demonstrates the potential to simultaneously accelerate recovery, improve component position, and reduce both length of stay and perioperative complication rates.

Center for Computer Assisted and Reconstructive Surgery  
New England Baptist Hospital  
125 Parker Hill Avenue, Suite 545 Boston, MA 02120  
stephenmurphy.org